

# Atypical Origin of Lateral Pectoral Nerve: A Case Report

BIDYARANI DEVI LOITONGBAM<sup>1</sup>, ANJULATA RAI<sup>2</sup>, JYOTI ARORA<sup>3</sup>, HARSHIKA KHATRI<sup>4</sup>



## ABSTRACT


In the present case, two Lateral Pectoral Nerves (LPN) were in the right axilla. The upper branch, superior LPN arose from the proximal part of the axilla deep to the clavicle from the anterior division of the upper trunk. This branch descends medially and enters the deep surface of the pectoralis major muscle. A larger LPN is seen originating from the distal part of the right lateral root of the median nerve at the lower part of the axilla, medial to the third part of the right axillary artery. This inferior LPN is 2 cm long, descends medially, and joins with the Medial Pectoral Nerve (MPN) forming ansa pectoralis. The branches from the ansa pierce the pectoralis minor muscle and enter the pectoralis major muscle. It supplies both the pectoral muscles. LPN fibers passing from the Lateral Cord (LC) through the lateral root of median have not been reported yet. The LPN is the main nerve of pectoralis major muscle. A thorough understanding of Pectoral Nerve (PN) anatomy is a must for surgeons practicing mastectomies, breast augmentation surgery, axillary dissection, harvesting pectoralis major muscle island flap, and dealing with trauma and fracture of the shoulder.

**Keywords:** Axilla, Brachial plexus, Clavicle, Pectoralis muscle

## CASE REPORT

During a routine dissection of the axillary region in the Anatomy Department, of formalin embalmed and preserved body of a male adult cadaver of approximately 65 years, multiple atypical branches were observed in the brachial plexus of both right and left axilla.

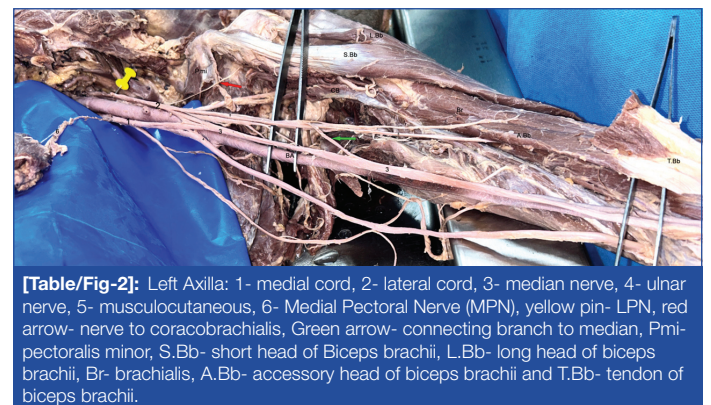
**The right brachial plexus:** Three Pectoral Nerve (PN)- two Lateral Pectoral Nerve (LPN) and one Medial Pectoral Nerve (MPN) were present. The right superior LPN originated from the anterior division of the upper trunk in the supraclavicular region. A second LPN/inferior LPN arose from the lateral root of the Median (Mn). This inferior LPN was 15 mm long, emerging from the lateral root of Mn, 4 mm above its junction with the medial root coming from the medial cord. The inferior LPN ran down and joined the MPN forming, ansa pectoralis [Table/Fig-1 a-c].



**[Table/Fig-1]:** Right Axilla: a) 1-lateral cord, 2-lateral root of median, 3- medial root of median, Green arrow- inferior LPN, Red arrow-MPN, and White arrow-superior LPN; P. Major- pectoralis major muscle; P.minor- pectoralis minor muscle; Mc- musculocutaneous nerve; and Mn- median nerve. Right axilla- b) Schematic representation and c) legends: 1- anterior division of upper trunk, 2- anterior division of middle trunk, 3- lateral cord, 4- musculocutaneous, 5- medial cord, 6- median, LR6- lateral root of median, MR6- medial root of median, 7- ulnar, black arrow-superior LPN, green arrow- inferior LPN, red arrow- Medial Pectoral Nerve (MPN), Pmi- pectoralis minor and BA- brachial artery.

The right LC was very short and formed by fusion of the anterior divisions of upper and middle trunk in the lower axilla anterolateral to third part of axillary artery [Table/Fig-1a]. The right LC then immediately divided into the right Musculocutaneous (Mcn) and lateral root of the right Median (Mn) [Table/Fig-1b,c]. The right Mcn gives a large communicating branch to the Mn in the upper arm. Mcn runs medial to the coracobrachialis muscle [Table/Fig-1a]. The MPN arises from the medial cord distal to the medial root of Mn. The right arm biceps brachii muscle had a third supernumerary head that originated from the medial surface of humerus and joins the main biceps tendon in the cubital fossa.

**Left axilla and arm:** In the left brachial plexus too, LC had atypical branching. The nerve to the left coracobrachialis originated directly from left LC in the upper axilla [Table/Fig-2]. The left Mcn does not pierce the left coracobrachialis muscle. The Mcn gave a communicating branch to the Mn in the mid- arm. The left biceps brachii also possesses a third accessory head that arises from the anteromedial surface of humerus superolateral to the brachialis muscle. The muscle tendon fuses with the main biceps tendon in the cubital fossa.



**[Table/Fig-2]:** Left Axilla: 1- medial cord, 2- lateral cord, 3- median nerve, 4- ulnar nerve, 5- musculocutaneous, 6- Medial Pectoral Nerve (MPN), yellow pin- LPN, red arrow- nerve to coracobrachialis, Green arrow- connecting branch to median, Pmi- pectoralis minor, S.Bb- short head of Biceps brachii, L.Bb- long head of biceps brachii, Br- brachialis, A.Bb- accessory head of biceps brachii and T.Bb- tendon of biceps brachii.

## DISCUSSION

The brachial plexus is associated with a high anomalous pattern of branching of all peripheral neural networks in the body [1]. The LC branches especially the Mcn frequently deviates from its classic course and connections. The variation and complexity of brachial plexus can be attributed to intricate route the spinal axons had

to traverse to reach the muscles. The muscles of upper limb are developed from the somites. The upper limb muscles are innervated by the ventral primary branch of spinal nerve C5 to T1. The motor axons had to follow a circuitous path to reach the flexor muscles. The axons penetrate the ventrocaudal side of the muscles [2]. The axon bundles growing towards the flexors of the upper limb had to navigate a double curve complex path as the Subclavian artery/axis formed an oblong obstruction. The LC is formed by meeting and merging the anterior division of C7 (middle trunk) and the anterior division of the upper trunk (fused anterior divisions of C5 and 6). This happens as the anterior fibers of C7 take a cranial turn instead of descending due to the presence of the subclavian artery while C5 and 6 descend normally. Any variability of the origin of the subclavian artery other than its usual origin from the seventh segmental artery can also affect the brachial plexus formation. The origin of the subclavian from the sixth segmental artery with associated tangential veins crossing cranially can affect the formation and branching of the LC [3].

There is a paucity of information on the anatomical details of PNs. The LPN is stated to originate either from the anterior divisions of the upper and middle trunks or as a single branch from the LC [4-6]. The LPN is larger than MPN and the main nerve to the pectoralis major muscle [7-9]. The PNs anatomy is important for surgeries in the pectoral region for breast carcinoma, breast cosmetic surgery while harvesting pectoralis major muscle flap, or PN denervation for treatment of spastic postmastectomy pain and neurotisation of obstetric brachial plexus palsy [10-12]. Knowing its anatomy is necessary to avoid injury to it while exploring trauma in the anterior shoulder or performing anterior approach procedures of the shoulder. Recently many researchers have reported the presence of two LPNs in majority of cases. Loukas M et al., in the study of 400 cadavers found the presence of two LPN in 60% of cases [12]. Arad E et al., reported 88% of presence of two LPN [1]. But, Prakash KG and Saniya K reported two LPN in 16% of cases with a single LPN in 62% [13]. The above case has two LPNs, the superior root carrying C5 and 6 fibers originating from the anterior division of the upper trunk. The inferior LPN arises from the distal part of the lateral root of the median. Hence, the C7 fibers of the LPN course through the LC and then onto the lateral root of median from where the inferior LPN is given off. Many studies have observed that the anterior division of upper trunk is the most common site of origin of LPN [1,14]. Lee KY reported two types of spinal origins of LPN s composed of C5, 6, and 7 and another only of C6 and C7 [15]. Padur AA et al., reported two cases of brachial plexus where the LPN was absent with multiple MPNs in both cases [16]. Boer N et al., observed LPN and MPN in all cadavers with 50% of the cadavers possessing two LPNs [17].

The authors did not come across any literature of the LPN deriving from the lateral root of the Mn. Most sites of atypical origin of LPN occurred proximal to LC.

## CONCLUSION(S)

The origin of LPN arising from the site distal to LC has not been reported yet. Hence, this case where the lower inferior LPN arose from the lateral root of median is novel and unique which need to be reported for future references.

## REFERENCES

- Arad E, Li Z, Sitzman JT, Agur MA, Clarke MH. Anatomic sites of origin of the suprascapular and lateral pectoral nerves within the brachial plexus. *Plast Reconstr Surg.* 2014;133(1):20-27. Doi: 10.1097/01.prs.0000436825.49580.82.
- Schoenwolf CG, Bleyl BS, Brauer RP, Frances-West HP ED. *Larsen's Human Embryology.* 5th ed. Philadelphia: Elsevier Churchill Livingstone; 2015.
- Leijnse NJ, de Bakker S, D'Herde K. The brachial plexus: Explaining its morphology and variability by a generic developmental model. *J Anat.* 2020;236(6):862-82. Doi: 10.1111/joa.13123.
- Standring S ED. *Gray's Anatomy: The Anatomical Basis of Clinical Practice.* 42nd ed. Edinburgh: Elsevier; 2021.
- Romanes GJ ED. *Cunningham's Manual of Practical Anatomy.* Vol. 1. 15th ed. Oxford: Oxford Medical Publications; 2008.
- Moore KL. *Moore's Clinically Oriented Anatomy.* 7th ed. Philadelphia: Wolters Kluwer; 2014.
- Behery EE. Innervation of the pectoralis major muscle: Anatomical study. *Ann Plast Surg.* 2012;68(2):209-14. Doi: 10.1097/SAP.0b013e318212f3d9.
- Hoffman WG, Elliot L. The anatomy of the pectoral nerves and its significance to the general and plastic surgeon. *Ann Surg.* 1987;205(5):504-06.
- Macchi V, Tiengo C, Porzionato A, Parenti A, Stecco C, Mazzoleni F, et al. Medial and lateral pectoral nerves: Course and branches. *Clin Anat.* 2007;20(2):157-62. Doi: 10.1002/ca.20328.
- David S, Balaguer T, Baque P, de Peretti F, Valla M, Lebreton E, et al. The anatomy of the pectoral nerves and its significance in breast augmentation, axillary dissection, and pectoral muscle flaps. *J Plast Reconstr Aesthet Surg.* 2012;65(8):1193-98. Doi: 10.1016/j.bjps.2012.03.032.
- Madhavan CM, Rajasekharan S, Varghese S. Anatomy of lateral pectoral nerve and its clinical significance. *Natl J Clin Anat.* 2022;11:79-83.
- Loukas M, Louis JR, Fitzsimmons J, Colborn G. The surgical anatomy of the ansa pectoralis. *Clin Anat.* 2006;19(8):685-93. Doi: 10.1002/ca.20315.
- Prakash KG, Saniya K. Anatomical study of pectoral nerves and its implications in surgery. *J Clin Diagn Res.* 2014;8(7):AC01-AC05. Doi: 10.7860/JCDR/2014/4545.
- Porzionato A, Macchi V, Stecco C, Loukas M, Tubbs RS, De Caro R. Surgical anatomy of the pectoral nerves and the pectoral musculature. *Clin Anat.* 2012;25(5):559-75. Doi: 10.1002/ca.21301.
- Lee KY. Anatomic variation of the spinal origins of the lateral and medial pectoral nerves. *Clin Anat.* 2007;20(8):915-18. Doi: 10.1002/ca.20556.
- Padur AA, Kumar N, Shanthakumar RS, Shetty DS, Prabhu SG, Patil J. Unusual and unique variant branches of lateral cord of brachial plexus and its clinical implications: A cadaveric study. *J Clin Diagn Res.* 2016;10(4):AC01-AC04. Doi: 10.7860/JCDR/2016/15244.7482.
- Boers N, Bleyls B, Schellekens PAP. The nerve supply to the pectoralis major: An anatomical study and clinical application of the denervation in subpectoral breast implant surgery. *J Plast Reconstr Aesthet Surg.* 2022;75:415-23. Doi: 10.1016/j.bjps.2021.05.055.

### PARTICULARS OF CONTRIBUTORS:

- Professor, Department of Anatomy, Atal Bihari Vajpayee Institute of Medical Sciences and Dr. Ram Manohar Lohia Hospital, New Delhi, India.
- Professor, Department of Anatomy, Atal Bihari Vajpayee Institute of Medical Sciences and Dr. Ram Manohar Lohia Hospital, New Delhi, India.
- Director, Professor and Head, Department of Anatomy, Atal Bihari Vajpayee Institute of Medical Sciences and Dr. Ram Manohar Lohia Hospital, New Delhi, India.
- Senior Resident, Department of Anatomy, Atal Bihari Vajpayee Institute of Medical Sciences and Dr. Ram Manohar Lohia Hospital, New Delhi, India.

### NAME, ADDRESS, E-MAIL ID OF THE CORRESPONDING AUTHOR:

Dr. Bidyarani Devi Loitongbam,  
7/13, FF, East Patel Nagar, New Delhi-110008, India.  
E-mail: shijabidya@gmail.com

### AUTHOR DECLARATION:

- Financial or Other Competing Interests: None
- Was informed consent obtained from the subjects involved in the study? No
- For any images presented appropriate consent has been obtained from the subjects. No

### PLAGIARISM CHECKING METHODS: [Jan H et al.]

- Plagiarism X-checker: Aug 14, 2024
- Manual Googling: Nov 04, 2024
- iThenticate Software: Nov 06, 2024 (17%)

### ETYMOLOGY: Author Origin

EMENDATIONS: 6

Date of Submission: Aug 13, 2024

Date of Peer Review: Sep 30, 2024

Date of Acceptance: Nov 08, 2024

Date of Publishing: Jan 01, 2025